

Effects of Glaukos[®] Trabecular Stent in the Treatment of Glaucoma

Pedro Arriola-Villalobos,¹ Laura Morales-Fernández,¹ José M Martínez-de-la-Casa² and Julián García-Feijoó³

1. Ophthalmology Unit, Clinico San Carlos Hospital Health Research Institute; 2. Ophthalmology Unit, Clinico San Carlos Hospital, Ophthalmology and Otorhinolaryngology Department, School of Medicine, Universidad Complutense, Clinico San Carlos Hospital Health Research Institute; 3. Ophthalmology Unit, Clinico San Carlos Hospital, Ophthalmology and Otorhinolaryngology Department, School of Medicine, Ophthalmic Research Institute, Universidad Complutense, Clinico San Carlos Hospital Health Research Institute, Cooperative Research Network on Age-Related Ocular Pathology, Visual and Life Quality, Health Institute Carlos III

Abstract

Micro-invasive glaucoma surgery (MIGS) is gaining interest in very recent years, due to a better safety profile and good tensional results, often associated to cataract surgery. Glaukos iStent[®] is the only FDA-approved device for micro-invasive glaucoma surgery. It connects the anterior chamber to Schlemm's canal by bypassing the trabecular meshwork, increasing the outflow facility. The Glaukos iStent is indicated for use in conjunction with cataract surgery for the reduction of intraocular pressure (IOP) in adult patients with mild to moderate open-angle glaucoma currently treated with ocular hypotensive medication. This article summarises the results of all the clinical and experimental studies published regarding iStent effectiveness and safety. Glaukos iStent, in conjunction with cataract surgery, is a safe and effective option in the treatment of open angle glaucoma, with a significant but modest IOP drop and a significant and more clinically relevant decrease in glaucoma medications, with no serious adverse events. Some aspects concerning the number of iStent used or other indications like ocular hypertension or secondary glaucoma remain under study, although good results in both clinical situations have been published. A new model of iStent has just been developed and its first clinical results are near to be published.

Keywords

Micro-invasive, glaucoma, surgery, iStent, cataract

Disclosure: Julian García-Feijoó is a consultant to the Glaukos Corporation. The remaining authors have no conflicts of interest to declare.

Received: 17 December 2012 **Accepted:** 20 January 2013 **Citation:** *European Ophthalmic Review*, 2013;7(1):10–3

Correspondence: Pedro Arriola-Villalobos, Ophthalmology Unit, Hospital Clinico San Carlos, C/Profesor Martin Lagos, s/n, 28040, Madrid, Spain. E: pedro_arriola@hotmail.com

In very recent years there is an increasing interest on micro-invasive glaucoma surgery (MIGS) procedures.¹ Traditional ab externo glaucoma surgical procedures (e.g., trabeculectomy, tubes, deep sclerectomy) are associated with significant risks and complications, whereas MIGS procedures are associated with mild and less frequent side events and do not limit other surgical options in the future. Moreover, MIGS procedures have a more rational approach to the aetiology of glaucoma, because the trabecular meshwork is the site of resistance to aqueous humor outflow in primary open-angle glaucoma (POAG). Surgical procedures involving the anterior chamber angle, such as goniotomy and trabeculotomy, are usually indicated for congenital glaucoma. In adults, the healing response after these surgical procedures prevents an adequate and maintained hypotensive effect.

Recently, alternative surgical procedures, such as silicone tubes,² Y-shaped bidirectional glaucoma tubes,³ the trabectome⁴ and the Hydrus, a three clock hour nitinol scaffold,⁵ which focus on the anterior chamber angle have been proposed to reduce post-operative scarring. The purpose of these devices is to reduce intraocular pressure (IOP) by draining the aqueous humor through the collector channels.

The Glaukos iStent[®] (Glaukos Corporation, Laguna Hills, California) is a 0.5 x 0.25 x 1 mm L-shaped, heparin-coated stent made of titanium (see *Figure 1*). The stent was designed to connect the anterior chamber

to Schlemm's canal by bypassing the trabecular meshwork, increasing the outflow facility and reducing the IOP.^{6–8} Glaukos iStent has received FDA approval for the treatment of glaucoma in June 2012, being the only FDA-approved device for the treatment of mild to moderate open-angle glaucoma.

Spiegel et al. described the surgical technique.⁹ The stent is ideal for implantation combined to phacoemulsification and the surgery can be performed under topical anaesthesia. The angle is easier to visualise and the surgery is easier to perform in pseudophakic eyes. To achieve a successful surgical outcome, the most important step is to have clear visualisation of the angle by tilting the operating microscope 30 degrees and turning the patient's head at least 45 degrees away from the surgeon. In combined surgery, when phacoemulsification has been completed and an intraocular lens has been inserted, the anterior chamber should be refilled with a cohesive viscoelastic. The surgical microscope and the patient's head then are repositioned and the angle is visualised with a gonio lens placed on the cornea. Finally, the inserter is introduced into the anterior chamber and the stent is placed into Schlemm's canal through the trabecular meshwork. The stent is implanted through a temporal approach in a nasal position. If two implants are used, one is placed inferonasally and the other superonasally. The stent should be parallel to the iris root with the rails located on the back wall of Schlemm's canal (see *Figure 2*).

The Glaukos iStent is indicated for use in conjunction with cataract surgery for the reduction of IOP in adult patients with mild to moderate open-angle glaucoma currently treated with ocular hypotensive medication. The iStent is contraindicated in eyes with primary or secondary angle closure glaucoma, including neovascular glaucoma, as well as in patients with retrobulbar tumour, thyroid eye disease, Sturge-Weber Syndrome or any other type of condition that may cause elevated episcleral venous pressure. Gonioscopy should be performed prior to surgery to exclude peripheral anterior synechiae (PAS), rubeosis and other angle abnormalities or conditions that would prohibit adequate visualisation of the angle that could lead to improper placement of the stent.

Several clinical studies involving Glaukos iStent have been published since the first pilot study in 2007,¹⁰ most of them combined with phacoemulsification, showing the effectiveness and safety of iStent in eyes with mild to moderate glaucoma and coexistent cataract (see Table 1).

Spiegel et al.^{9,11} studied stent implantation with concurrent cataract surgery in glaucoma patients at six and 12 months of follow-up, with significant IOP and antiglaucomatous drug use reduction in both studies.

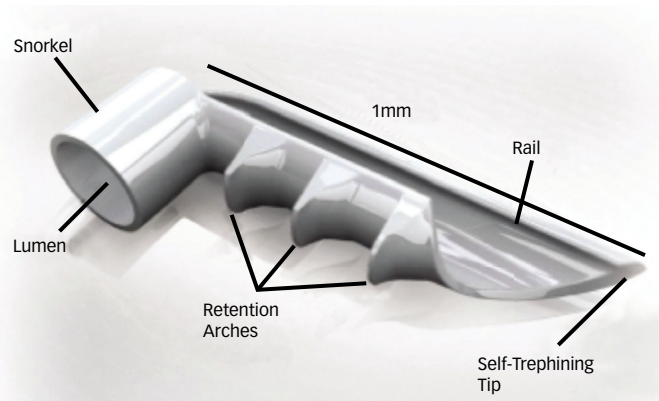
Fernandez-Barrientos et al.¹² established a significant increase in trabecular outflow in cataract extraction with concomitant iStent implantation versus cataract surgery alone (275 and 46 %, respectively, $p=0.02$).

Fea¹³ published in 2010 the first randomised study comparing outcomes after phacoemulsification alone versus phacoemulsification combined with one stent implantation, showing that the IOP was statistically significantly lower in the combined group than in the control group at the end of follow up ($p=0.042$). At 15 months, the mean number of medications was lower in the combined group than in the control group (0.4 ± 0.7 and 1.3 ± 1.0 , respectively; $p=0.007$), as was the proportion of patients on ocular hypotensive medication (33 and 76 %, respectively).

Samuelson et al.¹⁴ published 1-year results in the largest prospective trial involving iStent. The study included 240 eyes with mild to moderate glaucoma, which were randomly assigned to cataract surgery and stent implantation or cataract surgery alone. The authors established two main outcomes. The primary efficacy measure was unmedicated IOP ≤ 21 mmHg at one year. A secondary measure was unmedicated IOP reduction ≥ 20 % at one year. The study met the primary outcome, with 72 % of treatment eyes versus 50 % of control eyes achieving the criterion ($p<0.001$). At one year, IOP in both treatment groups was statistically significantly lower from baseline values. Sixty-six per cent of treatment eyes versus 48 % of control eyes achieved ≥ 20 % IOP reduction without medication ($p=0.003$).

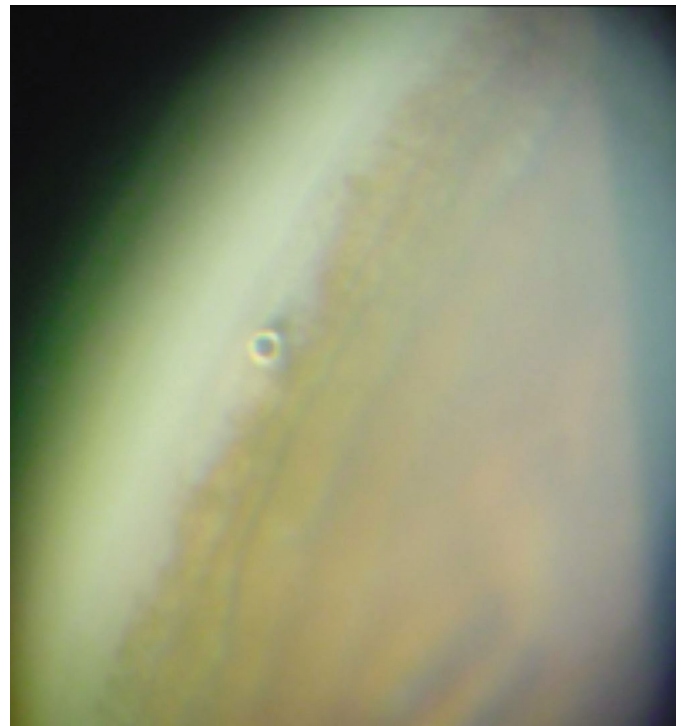
Craven et al.¹⁵ have just published 2-year data from the same study. At 24 months, the proportion of patients with IOP ≤ 21 mmHg without ocular hypotensive medications was significantly higher in the stent group than in the control group ($p=0.036$). Overall, the mean IOP was stable between 12 months and 24 months (17.0 ± 2.8 mmHg and 17.1 ± 2.9 mmHg, respectively) in the stent group but increased (17.0 ± 3.1 mmHg to 17.8 ± 3.3 mmHg, respectively) in the control group. Ocular hypotensive medication was statistically significantly

Figure 1: GTS-100 iStent®



The stent is a 0.5 x 0.25 x 1 mm L-shaped, stent made of titanium. It has a snorkel (diameter: 0.1 mm) and retention arcs. The self-trephine tip allows for an easy introduction into Schlemm's canal.

Figure 2: One Week After Surgery – iStent® in the Schlemm's Canal, Parallel to the Iris Plane and with the Snorkel Away from the Iris



lower in the stent group at 12 months; it was also lower at 24 months, although the difference was no longer statistically significant.

Our group recently published the study with the longer follow up,¹⁶ almost 54 months. Mean IOP was reduced from 19.42 ± 1.89 mmHg to 16.26 ± 4.23 mmHg ($p=0.002$) at the end of follow up, indicating a 16.33 % decrease in intraocular pressure. The mean number of pressure-lowering medications used by the patients fell from 1.32 ± 0.48 to 0.84 ± 0.89 ($p=0.046$). In 42 % of patients, no antiglaucomatous medications were used at the end of follow up.

In almost all the studies just one iStent is implanted. Using a theoretical *in vitro* perfusion model, some authors predicted that more than just one iStent may increase facility of outflow and reduce IOP versus a single implant.⁶ Better IOP result at 1 year of follow up from

Table 1: Results after Glaukos iStent® Implantation Combined with Cataract Surgery

	iStent Number	Eyes	Follow up (Months)	Mean IOP Reduction (mmHg)	Mean Reduction in Medications
Spiegel et al. ⁹	1	48	6	5.7 ± 3.8	1.5 ± 0.7 versus 0.5 ± 0.8 [†]
Spiegel et al. ¹¹	1	42	12	4.4 ± 4.5	1.2 ± 0.7
Fernandez-Barrientos et al. ¹²	2	17	12	6.57 ± 2.95	1.12 ± 0.48 versus 0 [†]
Samuelson et al. ¹⁴	1	106	12	1.5 ± 3.0	1.4 ± 0.8
Belovay et al. ¹⁷	2–3	53	12	18.0 ± 4.0 versus 14.3 ± 2.9 [†]	2.0 ± 1.4
Fea ¹³	1	12	15	3.2 ± 3.0	2.0 ± 0.9 versus 0.4 ± 0.7 [†]
Craven et al. ¹⁵	1	98	24	18.6 ± 3.4 versus 17.1 ± 2.9 [†]	1.6 ± 0.8 versus 0.3 ± 0.6 [†]
Arriola-Villalobos et al. ¹⁶	2	19	53.68 ± 9.26	3.16 ± 3.9	0.47 ± 0.96

Outcome variables reported in the available studies addressing the efficacy of iStent placement to treat glaucoma combined with phacoemulsification to treat cataract ([†]data not available, mean pre-op versus mean post-op shown). IOP = Intraocular pressure.

Fernandez-Barrientos et al.¹² study versus other studies with just one iStent is consistent with that hypothesis. One very recently published article studied the efficacy of multiple iStent combined with cataract surgery in POAG and cataract.¹⁷ The study involved 53 eyes, 28 had implantation of two stents and 25 had implantation of three stents. Overall, there was a significant decrease in IOP and use of medications at the end of follow up. The IOP reduction was greater in the 3-stent-group, with a mean reduction of 3.9 versus 3.5 mmHg in the 2-stent-group (p=0.76). 71 % of the eyes in the 2-stent-group and 84 % of the eyes in the 3-stent-group achieved target IOP. There was a 64 % reduction in topical ocular hypotensive medications in the 2-stent-group and 85 % reduction in the 3-stent-group. The 3-stent-group was on significantly fewer medications at one year than the 2-stent-group (0.4 and 1.0 respectively, p=0.04). The authors conclude that the study, despite its limitations (being the lack of control group the most important), suggests that the implantation of multiple stents lead to better efficacy results, although a masked randomised trial is needed to better evaluate the relative efficacy of two versus three stents.

Good safety outcomes are common in all the studies, with no serious adverse events after iStent implantation. Stent obstruction or malposition was the most frequent complication in clinical studies, with no late-onset complications or complications commonly associated with traditional ab externo glaucoma surgical procedures, such as endophthalmitis, hypotony or bleb-related problems.

iStent implantation can also be used to treat secondary glaucoma,¹⁸ including pigmentary and pseudoexfoliative glaucoma,¹⁶ steroid glaucoma¹⁹ or traumatic glaucoma. Even patients with ocular hypertension (OHT) and cataract may benefit from iStent implantation combined to phacoemulsification.

A second-generation iStent (GTS-400) has recently been developed by Glaukos. The G2-M-IS iStent inject system comes preloaded with two GTS-400 stents, which allows the implantation of two GTS-400 stents without having to withdraw the inserter from the anterior chamber

and use a second inserter. A prospective laboratory investigation using normal human donor eyes has determined that the new Glaukos iStent increased outflow facility in human anterior segment culture, with a further increase in outflow facility when a second iStent was used.²⁰ We have evaluated the efficacy and safety of the new Glaukos iStent in combination with phacoemulsification in 20 patients with POAG, pseudoexfoliative glaucoma or OHT and cataract, with significant reductions achieved in IOP and number of antiglaucomatous medications at 1-year follow up.²¹ Some clinical trials are under way involving new Glaukos GTS-400 iStent.

All these results show that iStent implantation is a safe and effective procedure to treat co-existent mild to moderate open-angle glaucoma or OHT and cataract, with all the advantages of a combined procedure. A significant IOP decrease is achieved, with a significant reduction in the use of antiglaucomatous drugs. This is crucial, because several studies have shown that the chronic use of antiglaucomatous medications may lead to ocular surface damage and conjunctival inflammation²² or even reduce the success rate of subsequent trabeculectomy.²³ iStent use can avoid the problems of compliance (long-term morbidity and nonadherence) associated with chronic use of multiple medications to control POAG, improving patient convenience and quality of life. The significant effect in IOP and use of drops is achieved with no significant side effects associated. iStent is an ab interno procedure, which reduces the IOP by bypassing the trabecular meshwork, draining the aqueous humor through the collector channels. It offers a more rapid and less invasive approach compared with other combined procedures and it spares the conjunctiva preserving options for success in more aggressive ab externo glaucoma surgeries if required.

On the other hand, IOP decrease after iStent implantation is modest; with an IOP drop significantly lower than traditional ab externo surgeries like trabeculectomy. Cost-effectiveness studies have not been performed, but we must consider the price of the iStent compare to the cost of years of treatment with antiglaucomatous drugs and quality of life affairs. In the near future more clinical articles evaluating long-term

results from iStent are expected. Besides, clinical data regarding new Glaukos iStent GTS-400 is close to be published, increasing surgical options with a safer and easier implantation technique and similar, if no better, results.

In conclusion, iStent combined with cataract surgery is a safe and effective procedure in the treatment of coexistent mild to moderate POAG and cataract. It can be a previous step to filtering surgery in patients with no advanced glaucoma and indication for cataract surgery. ■

1. Saheb H, Ahmed II, Micro-invasive glaucoma surgery: current perspectives and future directions, *Curr Opin Ophthalmol*, 2012;23:96–104.
2. Spiegel D, Kobuch K, Trabecular meshwork bypass tube shunt: initial case series, *Br J Ophthalmol*, 2002;86:1228–31.
3. Brown RH, Lynch MG, Glaucoma bypass surgery: initial clinical studies with the GMP bi-directional glaucoma shunt. 12th American Glaucoma Society Annual Meeting, 2002; abstract 19.
4. Minckler DS, Baerveldt G, Alfaro MR, Francis BA, Clinical results with the trabectome for treatment of open-angle glaucoma, *Ophthalmology*, 2005;112:962–7.
5. Camras LJ, Yuan F, Fan S, et al., A novel Schlemm's Canal scaffold increases outflow facility in a human anterior segment perfusion model, *Invest Ophthalmol Vis Sci*, 2012;53:6115–21.
6. Bahler CK, Smedley GT, Zhou J, Johnson DH, Trabecular bypass stents decrease intraocular pressure in cultured human anterior segments, *Am J Ophthalmol*, 2004;138:988–94.
7. Zhou J, Smedley GT, A trabecular bypass flow hypothesis, *J Glaucoma*, 2005;14:74–83.
8. Zhou J, Smedley GT, Trabecular Bypass. Effect of Schlemm canal and collector channel dilation, *J Glaucoma*, 2006;15:446–55.
9. Spiegel D, García-Feijóo J, García-Sánchez J, Lamielle H, Coexistent primary open-angle glaucoma and cataract: preliminary analysis of treatment by cataract surgery and the iStent trabecular micro-bypass stent, *Adv Ther*, 2008;25:453–64.
10. Spiegel D, Wetzel W, Haffner DS, Hill RA, Initial clinical experience with the trabecular micro-bypass stent in patients with glaucoma, *Adv Ther*, 2007;24:161–70.
11. Spiegel D, Wetzel W, Neuhann T, et al., Coexistent primary open-angle glaucoma and cataract: interim analysis of a trabecular micro-bypass stent and concurrent cataract surgery, *Eur J Ophthalmol*, 2009;19(3):393–9.
12. Fernández-Barrientos Y, García-Feijóo J, Martínez-de-la-Casa JM, et al., Fluorophotometric study of the effect of the glaukos trabecular microbypass stent on aqueous humor dynamics, *Invest Ophthalmol Vis Sci*, 2010;51:3327–32.
13. Fea AM, Phacoemulsification versus phacoemulsification with micro-bypass stent implantation in primary open-angle glaucoma: randomized double-masked clinical trial, *J Cataract Refract Surg*, 2010;36:407–12.
14. Samuelson TW, Katz LJ, Wells JM, et al., US iStent Study Group. Randomized evaluation of the trabecular micro-bypass stent with phacoemulsification in patients with glaucoma and cataract, *Ophthalmology*, 2011;118:459–67.
15. Craven ER, Katz LJ, Wells JM, Giamporcaro JE, iStent Study Group. Cataract surgery with trabecular micro-bypass stent implantation in patients with mild-to-moderate open-angle glaucoma and cataract: Two-year follow-up, *J Cataract Refract Surg*, 2012;38:1339–45.
16. Arriola-Villalobos P, Martínez-de-la-Casa JM, Díaz-Valle D, et al., Combined iStent trabecular micro-bypass stent implantation and phacoemulsification for coexistent open-angle glaucoma and cataract: a long-term study, *Br J Ophthalmol*, 2012;96:645–9.
17. Belovay GW, Naqi A, Chan BJ, et al., Using multiple trabecular micro-bypass stents in cataract patients to treat open-angle glaucoma, *J Cataract Refract Surg*, 2012;38:1911–7.
18. Buchacra O, Duch S, Milla E, Stirbu O, One-year analysis of the iStent trabecular microbypass in secondary glaucoma, *Clin Ophthalmol*, 2011;5:321–6.
19. Morales-Fernandez L, Martínez-De-La-Casa JM, García-Feijoo J, et al., Glaukos® trabecular stent used to treat steroid-induced glaucoma, *Eur J Ophthalmol*, 2012;22:670–3.
20. Bahler CK, Hann CR, Fjeld T, et al., Second-generation trabecular meshwork bypass stent (iStent inject) increases outflow facility in cultured human anterior segments, *Am J Ophthalmol*, 2012;153:1206–13.
21. Arriola-Villalobos P, Martínez-de-la-Casa JM, Díaz-Valle D, et al., Mid-term evaluation of the new Glaukos iStent with phacoemulsification in coexistent open-angle glaucoma or ocular hypertension and cataract, *Br J Ophthalmol* (in press).
22. Baudouin C, Pisella PJ, Fillacier K, et al., Ocular surface inflammatory changes induced by topical antiglaucoma drugs: human and animal studies, *Ophthalmology*, 1999;106:556–63.
23. Broadway DC, Grierson I, O'Brien C, et al., Adverse effects of topical antiglaucoma medication. II. The outcome of filtration surgery, *Arch Ophthalmol*, 1994;112:1446–54.